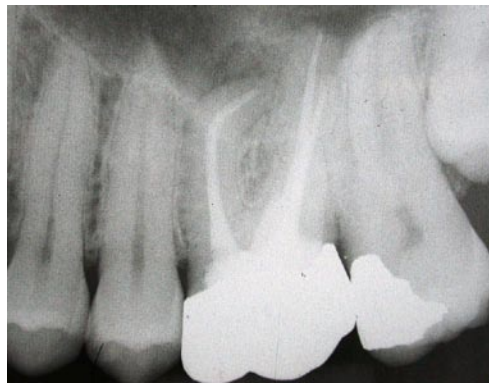
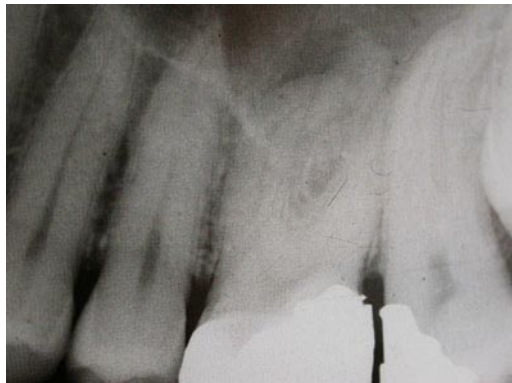
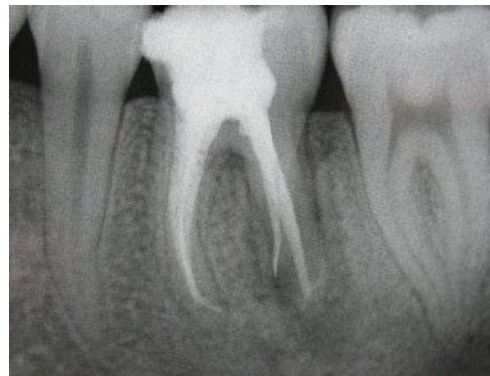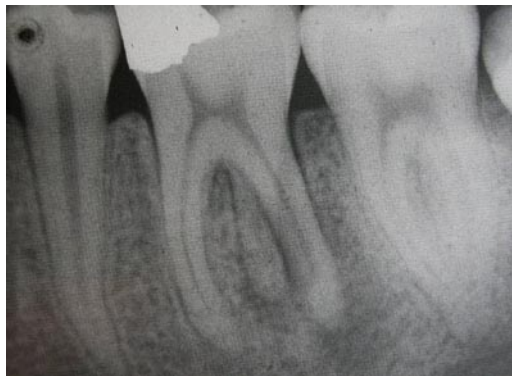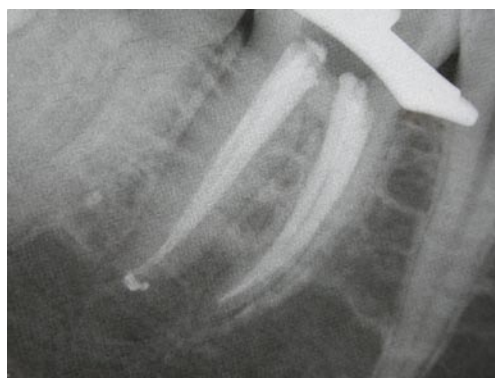
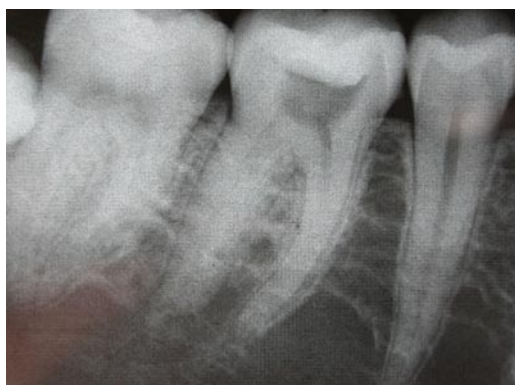The following cases have been completed by myself in practice; please do not copy them.



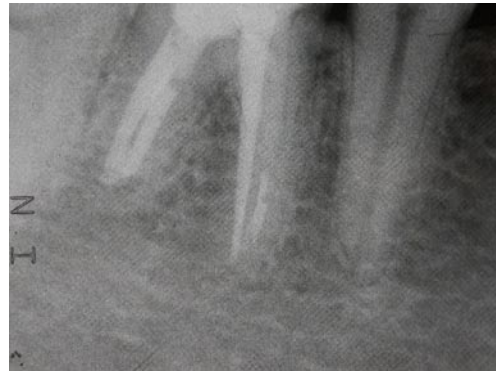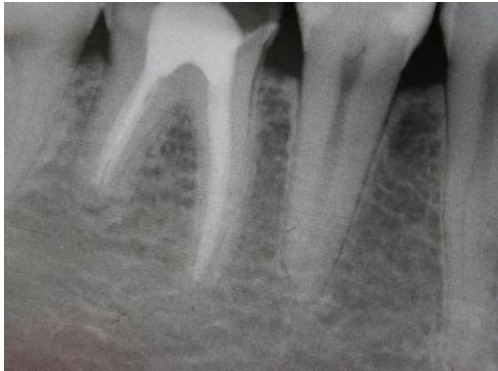
Treatment of Chronic apical periodontitis associated with infected necrotic pulp.



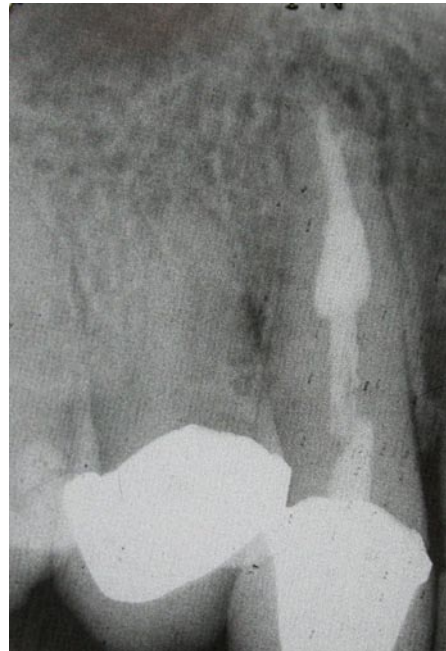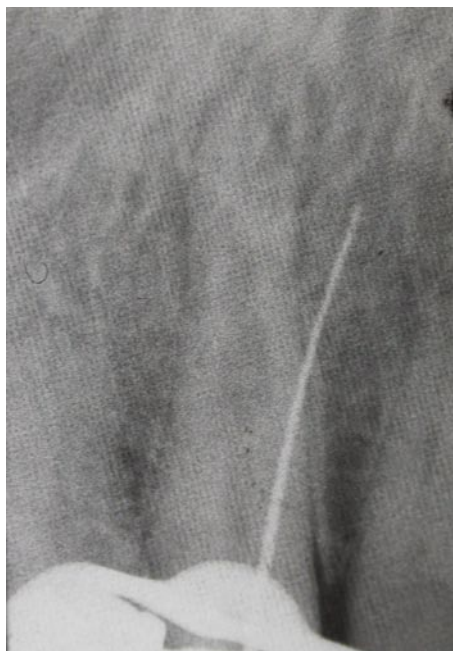Root canal treatment of a LL6 with three roots.



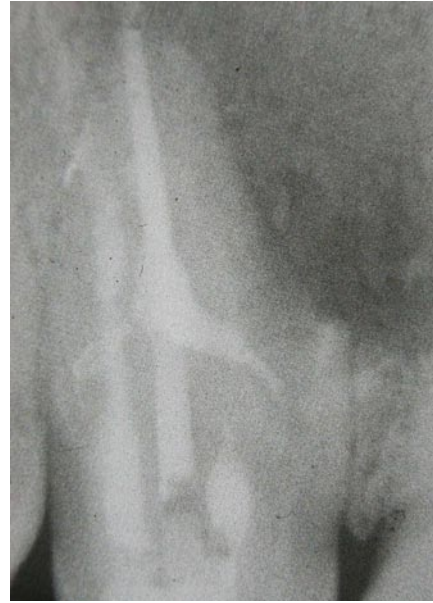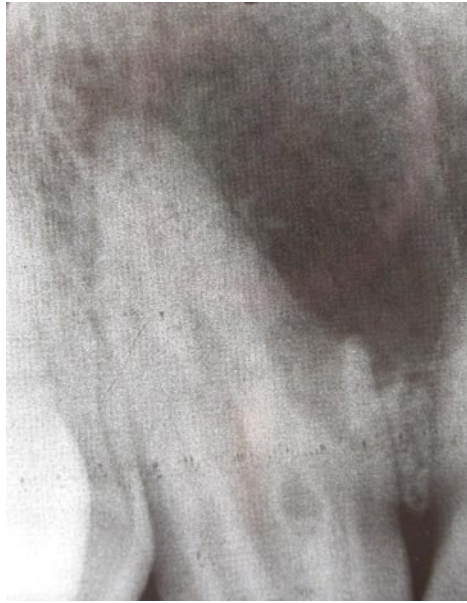Root canal re-treatment of an LR6 with chronic apical periodontitis associated with an infected necrotic pulp.



Root canal re-treatment of a LR6 with apical periodontitis associated with an existing root filling. Placement of a fibre post in the Mesiolingual canal and composite core in the coronal 4mm of the distal canals.



Repair of perforated UR3 and treatment of an infected necrotic pulp and an internal resorption.



Root canal treatment of an UR2 with Dens in Dente, showing signs of healing after 6 months post operatively.